

CONGENITAL ADRENAL HYPERPLASIA WITH CONCOMITANT MULLERIAN AGENESIS: A RARE OCCURRENCE IN 46 XX DISORDERS OF SEXUAL DEVELOPMENT

Wahyuni Z^{1*}, Yuad H², Margareta Sari Y³

¹Resident of Obstetrics and Gynecology Specialist Program, Andalas University, Indonesia

²Reproductive Endocrinology and Infertility Department of Dr. M. Djamil Hospital, Indonesia

³Urology and Reconstructive Surgery Department of Dr. M. Djamil Hospital, Indonesia
Email: wahyunizulfia179@gmail.com*

Abstract

The most common cause of 46 XX DSD is due to congenital adrenal hyperplasia with varying degrees of virilization. Females with CAH do not produce an anti-mullerian hormone (AMH), therefore the internal genitalia, which are Mullerian derivatives, develop normally. We report a unique case of CAH with aplasia of the uterus and upper vagina. The clinical, laboratory, and imaging findings of the patient are presented with a review of the literature. We report an ongoing case of a 20-year-old patient with ambiguous genitalia and primary amenorrhea. On physical examination, we found that she had an underdeveloped breast and clitoral virilization with separate urethral and vaginal openings. We performed a G-banded chromosome analysis, with 46 XX results. Laboratory test showed her 17-hydroxyprogesterone level was immensely elevated, while her FSH, LH, and estradiol level was below normal. Ultrasound imaging revealed the absence of uterus and cervix. Nevertheless, we found a diminutive uterine remnant during diagnostic laparoscopy with normal ovaries and fallopian tubes. On vaginoscopy examination, we found her vagina to be 5 cm long with blind end. In the presence of primary amenorrhea in patients with CAH, it is important to investigate for possible associated mullerian anomalies.

Keywords: *Congenital, Adrenal Hyperplasia, Concomitant Mullerian Agenesis*

Introduction

Ambiguous genitalia is a sex development disorder that is chromosomal, gonadal, and anatomically atypical which is generally characterized by the presence of external genital organs that are not male or female or have features of both sexes (Krishnan & Wisniewski, 2014);(Rajuddin & Fauzan, 2018);(Mehmood & Rentea, 2023). Terminology, such as hermaphrodite, pseudo-hermaphrodite, and intersex have now been replaced by Disorders of Sexual Development (DSD) (Crouch, 2022). The most common

How to cite:	Wahyuni Z, Yuad H, Margareta Sari Y (2023) Congenital Adrenal Hyperplasia with Concomitant Mullerian Agenesis: A Rare Occurance in 46 XX Disorders of Sexual Development, <i>Syntax Literate</i> (8) 12, https://doi.org/10.36418/syntax-literate.v8i10
E-ISSN:	2548-1398
Published by:	Ridwan Institute

cause is congenital adrenal hyperplasia, which is responsible for 90-95% of these cases (Mampilly, Ananthamurthy, Mohanty, & Das, 2022);(Mehmood & Rentea, 2023).

Congenital Adrenal Hyperplasia (CAH) is the term used to describe a group of genetically determined disorders of defective steroidogenesis resulting in variable deficiencies of cortisol and/or aldosterone end products that simultaneously lead to the accumulation of androgens and their virilizing effects (New et al., 2000). Mayer-Rokitansky-Syndrome Küster-Hauser (MRKH), also referred to as Müllerian aplasia, is a congenital disorder characterized by aplasia of the uterus and upper vagina in women with normal secondary sex characteristics and a normal female karyotype (46XX) (Patnaik, Brazile, Dandolu, Ryan, & Liao, 2015);(Herlin, Petersen, & Brännström, 2020).

In this case, we present patients with ambiguous genitalia with 46XX karyotyping results, increased levels of 17-hydroxyprogesterone, and aplasia of the uterus and upper vagina. A 20-year-old patient, self-identified as female, came to Reproductive Endocrinology and Infertility Polyclinic at RSUP Dr. M. Djamil Padang with a chief complaint of primary amenorrhea. She denied having cyclical lower abdominal pain. The patient admitted that her breasts did not grow while her pubic hair started to grow when she was 12 years old.

The patient was raised as a woman, feels like a woman, and has sexual attraction towards men. The patient urinates from the opening at the bottom of her genitalia. There are no complaints of urination or defecation. The patient is the 3rd child of 4 siblings, born spontaneously after a term pregnancy. There was no history of maternal exposure to androgens (testosterone, progesterone, aldosterone, glucocorticoids) or pesticides (dichlorodiphenyltrichloroethane, DDT), which cause endocrine disruption or virilization during pregnancy. Moreover, there was no history of hospitalization or vomiting in childhood. There was no history of similar complaints or unexplained infant deaths in the family.

On physical examination we found her height was 152 cm, weight 42 kg and vital signs are in normal range. She had excessive facial hair. According to the modified Ferriman-Gallwey scoring system, her hirsutism score was 10 (moderate level) (Ilagan, Paz-Pacheco, Totesora, Clemente-Chua, & Jalique, 2019). She also had moderate nodulocystic acne and untreated cleft palate. No neck enlargement and skeletal abnormalities were found.

The patient's breast was underdeveloped (Tanner stage M2) (Fig 1A), while the pubic hair growth seemed normal (Tanner stage P4) (Fig 1B). A structure resembling a penis was found \pm 4 cm in size. There were no palpable testes (Fig 1B). There is no labial fusion. The external urethral orifice is 0.5 cm below the "penis". A separate pinpoint vaginal introitus was seen 0,5 cm below the urethral orifice (Fig 1C) [Prader stage 4].

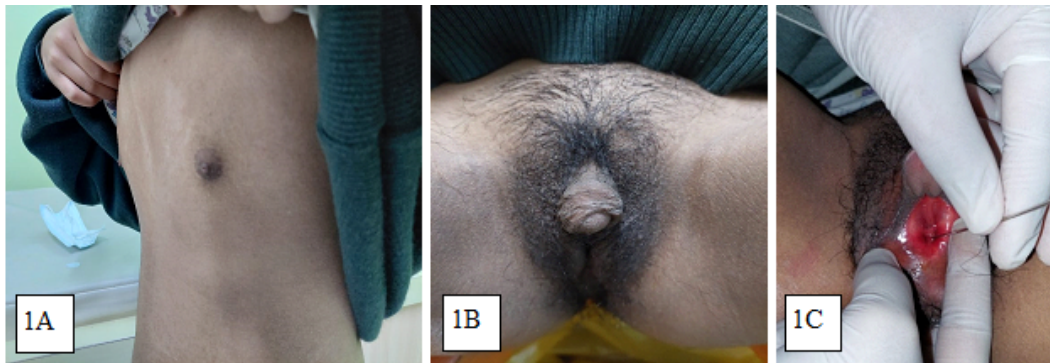

Fig 1. Physical examination findings

Ultrasonographic investigations did not reveal a clear image of the uterus, fallopian tubes, and cervix (Fig2A-2D).

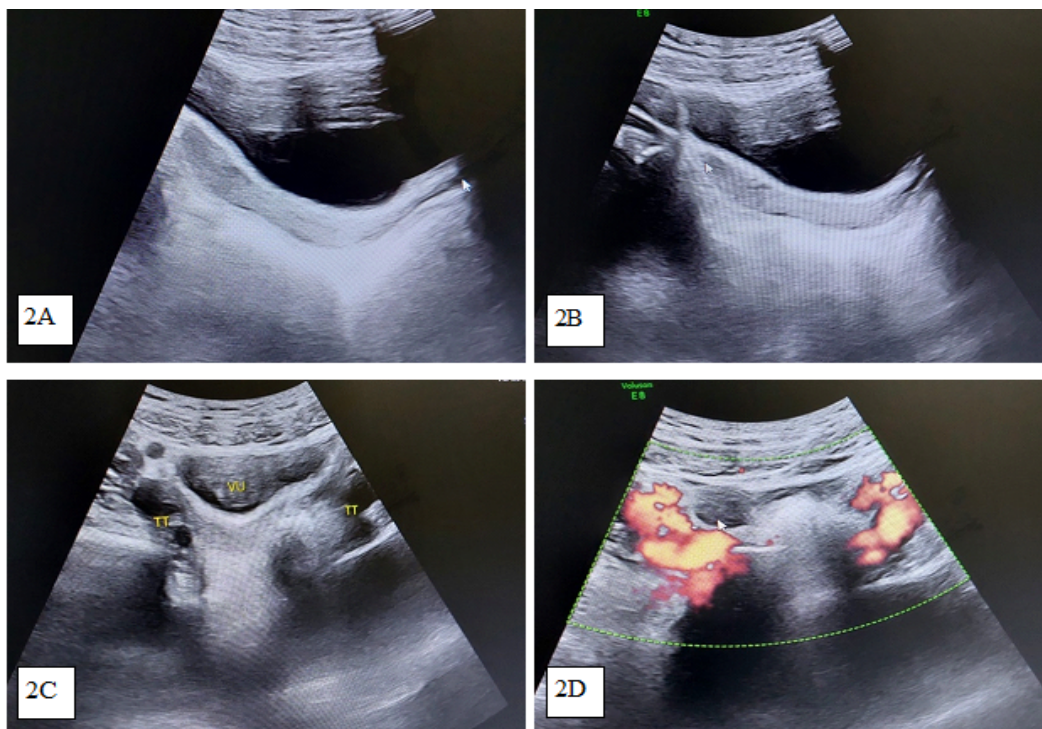


Fig 2. Ultrasonographic findings: unclear image of the uterus, fallopian tubes, and cervix

Subsequently, karyotyping of peripheral blood was performed and revealed a 46XX karyotype. On laboratory examination, the 17-hydroxyprogesterone (17-OHP) level was significantly increased to 176.93 ng/mL (normal female, ≤ 2.85 ng/mL). The LH, FSH, and estradiol level was low: 2.21 mIU/mL, 3.06 mIU/mL, and 18.0 pg/mL, respectively. The cortisol level in this patient was normal (5,1 ug/dl). Complete blood count, renal function test, lipid profile, and electrolyte status were all within normal limits. We have not conducted tests for androgens and progesterone levels (not covered by the insurance).

Congenital Adrenal Hyperplasia with Concomitant Mullerian Agenesis: A Rare Occurrence in 46 XX Disorders of Sexual Development

We later performed a diagnostic pelvic laparoscopy. Both ovaries and fallopian tubes appeared normal in size and shape. There was a band-shaped uterine remnant the size of a peanut (Fig 3A, 3B). On cystoscopy examination, we found the urethra, bladder, and ureteral orifice appeared normal (Fig 4A, 4B). On vaginoscopy, we found the vagina to be 5 cm long with a blind end. We could not identify the cervical portion (Fig 5A, 5B).

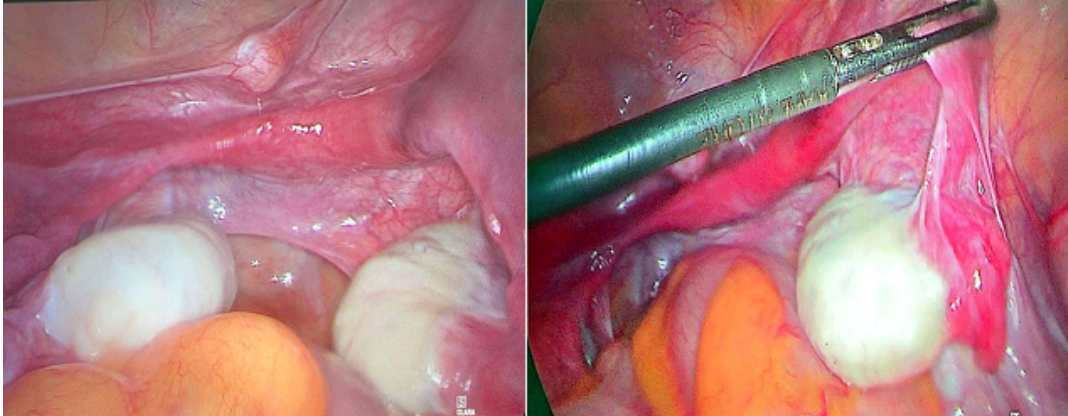


Fig 3. Pelvic laparoscopy findings

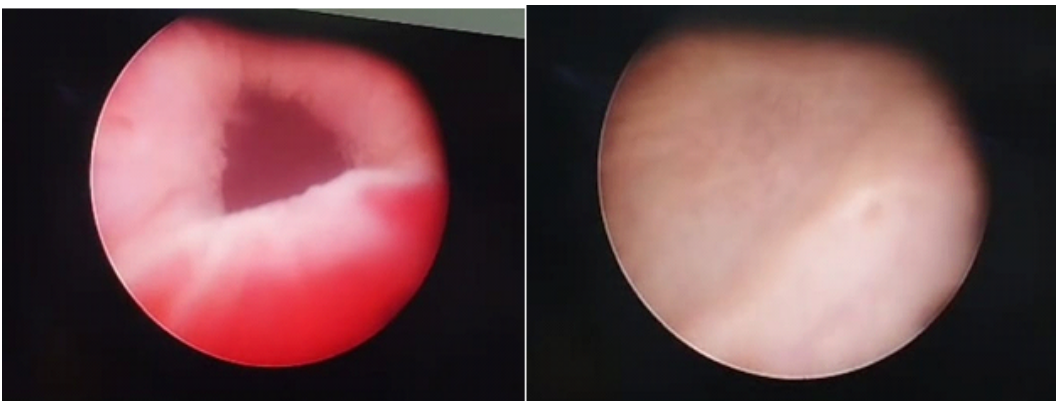


Fig 4. Cystoscopy findings

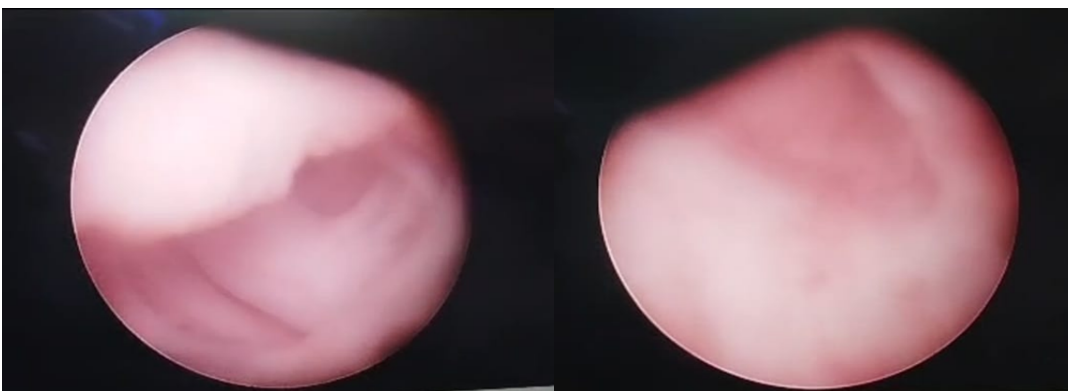


Fig 5. Vaginoscopy findings

Based on the history taking, physical examination, and investigations performed on this patient, a diagnosis of simple virilizing congenital adrenal hyperplasia with aplasia of the uterus (suspected MRKH syndrome) was established. The patient was treated with oral dexamethasone 0,25 mg once daily and also combined oral contraceptive pill (containing ethinylestradiol 0,03 mg and levonorgestrel 0,15 mg) once daily. She had clitoral hood reduction surgery for the clitoromegaly.

Research Methods

The research design used in this research is qualitative descriptive with a case study strategy. In the case study of a 20-year-old patient with ambiguous genitalia and primary amenorrhea, a systematic approach was taken to investigate the possible causes and associated conditions. The following methods and tests were employed:

- 1) Physical Examination: A thorough examination was conducted to assess the patient's external and internal genitalia, including the breasts, clitoris, urethra, and vagina.
- 2) G-banded Chromosome Analysis: A chromosomal analysis was performed to determine the patient's karyotype and identify any chromosomal abnormalities that may be associated with the patient's condition.
- 3) Laboratory Tests: The patient's hormonal levels were measured, including 17-hydroxyprogesterone, follicle-stimulating hormone (FSH), luteinizing hormone (LH), and estradiol. These tests helped to identify any hormonal imbalances that may be contributing to the patient's condition.
- 4) Ultrasound Imaging: Ultrasound imaging was used to assess the patient's internal reproductive organs, including the uterus, cervix, ovaries, and fallopian tubes.
- 5) Diagnostic Laparoscopy: A diagnostic laparoscopy was performed to further examine the patient's internal reproductive organs and identify any abnormalities.
- 6) Vaginoscopy: A vaginoscopy examination was conducted to assess the patient's vagina for any abnormalities or anomalies.

By employing this systematic approach, the healthcare professionals were able to identify the patient's condition as congenital adrenal hyperplasia (CAH) with aplasia of the uterus and upper vagina. This methodical approach allowed for a comprehensive understanding of the patient's condition and aided in the diagnosis and treatment process.

Results and Discussion

Disorders of sex devolvement (DSD), formerly known as ambiguous genitalia or intersex disorders, represent a spectrum of inherited conditions in which chromosomal, gonadal sex or anatomy is atypical (Mampilly et al., 2022);(Mehmood & Rentea, 2023). In this case, a karyotyping examination was carried out as a diagnostic first step according to a diagnostic algorithm for patients with ambiguous genitalia, in this patient the result was 46XX. The next examination was the 17-OHP hormone (17-hydroxyprogesterone) which was highly increased.

Congenital Adrenal Hyperplasia with Concomitant Mullerian Agenesis: A Rare Occurrence in 46 XX Disorders of Sexual Development

Elevated levels suggest congenital adrenal hyperplasia as a cause of virilization in this patient. CAH is 95% caused by mutations in the CYP21A2 gene, which codes for the adrenal steroid 21-hydroxylase. The salt-losing type is regarded as the classic and most severe form of 21-hydroxylase deficiency, in which cortisol production is virtually absent, and the aldosterone production is diminished leading to salt wasting, failure to thrive, and potentially fatal hypovolemia and shock (Twayana et al., 2022). Based on the overall health and cortisol level in this patient, we concluded that the patient had a less severe form of the disease (simple virilizing type).

In contrast to the virilization of the external genitalia, internal female genitalia, the uterus, fallopian tubes, and ovaries, develop normally. Females with CAH do not produce anti-Müllerian hormone (AMH), which is produced by the testicular Sertoli cells. Internal female structures are Müllerian derivatives and are not androgen-responsive. Therefore, the affected female is born with virilized external genitalia but normal female internal genitalia has the possibility of normal fertility (New et al., 2000).

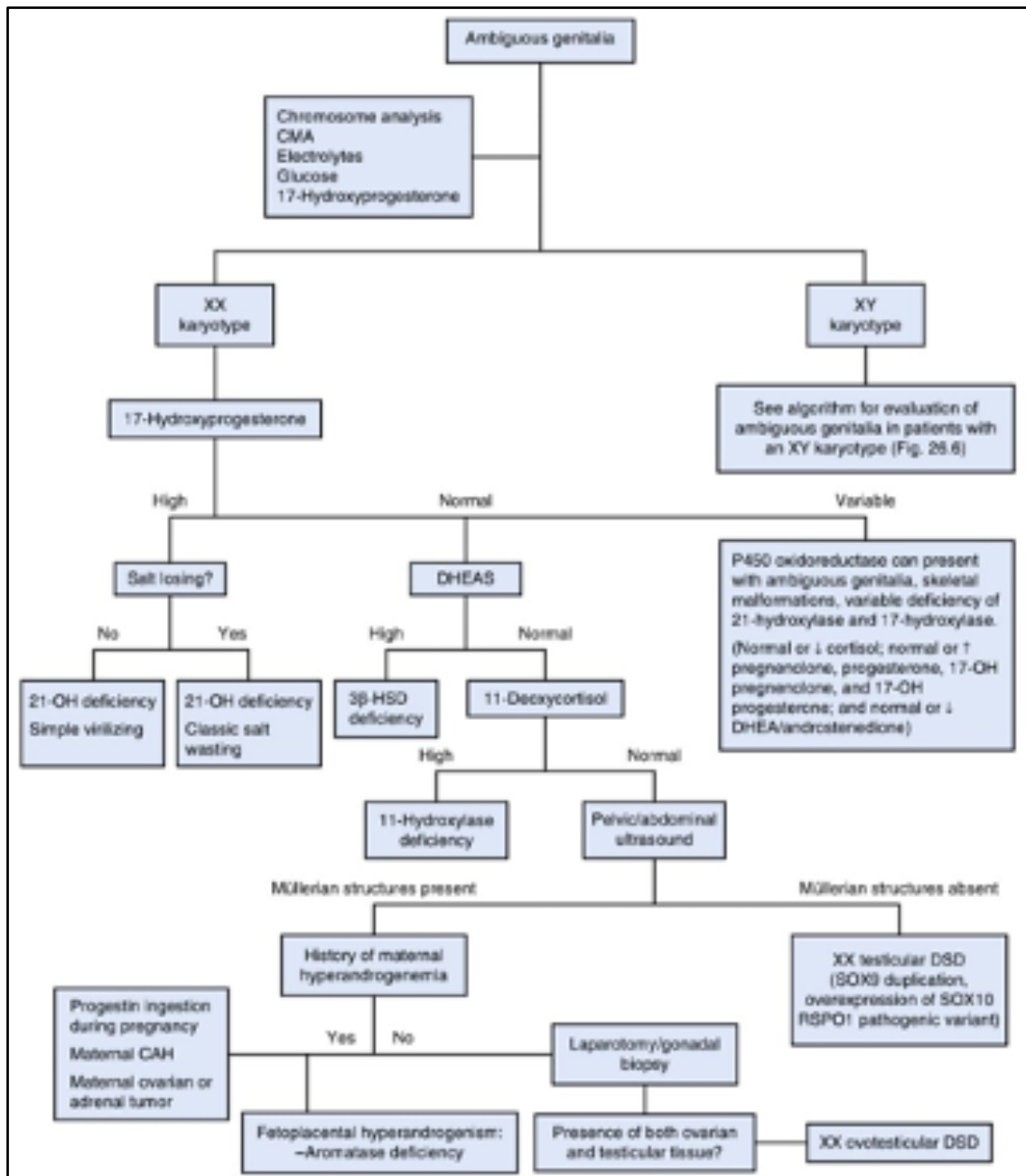


Fig 6. Diagnostic Algorithm for patients with ambiguous genitalia with karyotype 46, XX7

CAH is known to alter the function of the hypothalamic–pituitary–ovarian axis. Potential aetiologies for the alterations to the hypothalamic–pituitary–ovarian axis include elevated androgens, elevated progesterone, expression of 5 α -reductase in the ovary, or even a direct glucocorticoid effect. Initial observations suggested that excess androgens are aromatized to estrogen, which could suppress gonadotropin secretion. Elevated androgen levels were also thought to inhibit folliculogenesis, albeit in rat models.

However, recent evidence has indicated that androgen excess impairs hypothalamic sensitivity to progesterone. This causes increased gonadotropin-releasing hormone pulse frequency, resulting in a preferential secretion of luteinizing hormone (LH). The hypersecretion of LH increases ovarian androgen production, which further potentiates and intensifies the effects of adrenal androgens. HPO axis suppression can occur which causes primary amenorrhea and failure of the patient's secondary sex development (Tanner mammary stage 2) (Mikhael, Punjala-Patel, & Gavrilova-Jordan, 2019);(Pereira & Lin-Su, 2018).

Patients with primary amenorrhea should undergo a pelvic ultrasound to confirm the internal anatomy. Furthermore, if the results are inconclusive it is necessary to conduct a Magnetic Resonance Imaging (MRI) examination or diagnostic laparoscopy. We did not perform an MRI scan on this patient due to the unavailability of a clinical pathway for this specific case (hence could not be covered by the insurance).

Laparoscopic findings suggest aplasia of the uterus, which is in line with MRKH syndrome diagnosis. Once an MRKH syndrome is diagnosed, it is important to have a comprehensive examination of various organ systems (especially the kidneys, vertebrae, and heart) considering that there is a possibility that the patient has MRKH syndrome with MURCS association (Morcel, Camborieux, fr, & Guerrier, 2007).

For patients with ovarian insufficiency, timely estrogen should be restarted, for secondary sexual characteristic development, to minimize bone loss and to achieve adequate uterine size for future fertility (Singh, Agarwal, Sinha, SINGH Sr, & SINHA, 2022). The optimal pubertal induction in women contains both estrogens and progesterone regimens. Different therapeutic options have been described over the years in the literature, but larger randomized trials are required to define the ideal approach.

The latest acquisitions in the field seem to propose that transdermal 17β -estradiol and micronized progesterone present the most physiological formulations available for this purpose. Since such preparations were not available in our center, we decided to use combined oral contraceptive pills once daily. On follow-up, after 30 days of steroid and hormonal therapy, menarche has still not occurred in this patient. We plan to continue the treatment for 6 months, with monthly laboratory and ultrasound examinations (Voutsadaki, Matalliotakis, & Ladomenou, 2022).

Conclusion

This rare occurrence, whether true or pure coincidence, highlights the possibility of a Mullerian anomaly in a patient with DSD. In the presence of a rudimentary or hypoplastic uterus, a straightforward diagnosis of MRKH syndrome is to be avoided without a prior hormonal profile test and subsequent hormone replacement therapy.

BIBLIOGRAPHY

- Crouch, Naomi S. (2022). Differences in Sex Development. *Paediatric and Adolescent Gynaecology for the MRCOG*, 87.
- Herlin, Morten Krogh, Petersen, Michael Bjørn, & Brännström, Mats. (2020). Mayer-Rokitansky-Küster-Hauser (MRKH) syndrome: a comprehensive update. *Orphanet Journal of Rare Diseases*, 15(1), 1–16.
- Ilagan, Ma Karen Celine C., Paz-Pacheco, Elizabeth, Totesora, Darwin Z., Clemente-Chua, Lyra Ruth, & Jalique, Jundelle Romulo K. (2019). The modified Ferriman-Gallwey score and hirsutism among Filipino women. *Endocrinology and Metabolism*, 34(4), 374–381.
- Krishnan, Sowmya, & Wisniewski, Amy B. (2014). Ambiguous genitalia in newborns. *Genetic Steroid Disorders*, 87–97.
- Mampilly, Neethu Tony, Ananthamurthy, Anuradha, Mohanty, Suravi, & Das, Kanishka. (2022). Disorders of Sexual Differentiation: A Clinicopathological and Histological Study. *Journal of Clinical & Diagnostic Research*, 16(2). <https://doi.org/10.7860/JCDR/2022/51433.15972>
- Mehmood, Khawar T., & Rentea, Rebecca M. (2023). Ambiguous genitalia and disorders of sexual differentiation. In *StatPearls [Internet]*. StatPearls Publishing.
- Mikhael, Sasha, Punjala-Patel, Advaita, & Gavrilova-Jordan, Larisa. (2019). Hypothalamic-pituitary-ovarian axis disorders impacting female fertility. *Biomedicines*, 7(1), 5.
- Morcel, Karine, Camborieux, Laure, fr, Programme de Recherches sur les Aplasies Müllériennes (PRAM) pram network. coordination@ univ rennes1., & Guerrier, Daniel. (2007). Mayer-Rokitansky-Küster-Hauser (MRKH) syndrome. *Orphanet Journal of Rare Diseases*, 2(1), 13.
- New, M., Yau, M., Lekarev, O., Lin-Su, K., Parsa, A., & Pina, C. (2000). Congenital adrenal hyperplasia.[Updated 2017 Mar 15]. *Endotext [Internet]*. South Dartmouth (MA): MDText. Com, Inc.
- Patnaik, Sourav S., Brazile, Bryn, Dandolu, Vani, Ryan, Peter L., & Liao, Jun. (2015). Mayer-Rokitansky-Küster-Hauser (MRKH) syndrome: a historical perspective. *Gene*, 555(1), 33–40.
- Pereira, Nigel, & Lin-Su, Karen. (2018). Reproductive Function and Fertility in Women with Congenital Adrenal Hyperplasia. *REPRODUCTIVE HEALTH*. <https://doi.org/10.33590/emjreprohealth/10314092>
- Rajuddin, & Fauzan. (2018). Disorders of Sex Development: Ambiguous Genitalia and Partial Androgen Insensitivity Syndrome. In *Proceedings of MICoMS 2017* (pp. 49–

Congenital Adrenal Hyperplasia with Concomitant Mullerian Agenesis: A Rare Occurrence in 46 XX Disorders of Sexual Development

52). Emerald Publishing Limited.

Singh, Ritu, Agarwal, Mukta, Sinha, Sudwita, SINGH Sr, RITU, & SINHA, SUDWITA. (2022). Challenges in the Diagnosis of Simple-Virilizing Congenital Adrenal Hyperplasia: A Case Report. *Cureus*, *14*(10). <https://doi.org/10.7759/cureus.29966>

Twayana, Anu R., Sunuwar, Neela, Deo, Sulav, Tariq, Wasiq B., Anjum, Azwar, Rayamajhi, Sushil, Shrestha, Bishayeeta, Twayana, Anu, & Tariq, Wasiq. (2022). Salt-Wasting Form of Congenital Adrenal Hyperplasia: A Case Report. *Cureus*, *14*(8).

Voutsadaki, Kleanthi, Matalliotakis, Michail, & Ladomenou, Fani. (2022). Hypogonadism in adolescent girls: treatment and long-term effects. *Acta Bio Medica: Atenei Parmensis*, *93*(5).

Copyright holder:

Wahyuni Z, Yuad H, Margareta Sari Y (2023)

First publication right:

Syntax Literate: Jurnal Ilmiah Indonesia

This article is licensed under:

