

VAGINAL PRIMARY MALIGNANT MELANOMA: A CASE REPORT

Octaviyana Nadia NS¹, Sukma Dewi Pawestri², Reyhan Aditya³, Fara Vitantri Diah C⁴, Chamim⁵

^{1,2,3}Department of Obstetric and Gynecology, Faculty of Medicine, Universitas Indonesia

^{4,5}Oncology Gynecology Consultant, Department of Obstetric and Gynecology, Fatmawati

Email: nadsyms@gmail.com, sukmadp@gmail.com, aditya.reyhan@yahoo.com, faravitantri@gmail.com, dr_chamim@yahoo.com

Abstract

Primary vaginal melanoma is an extremely rare gynaecological malignancy comprising less than 0.2% of all melanomas. Vaginal melanoma is a very rare and aggressive type of gynecologic cancer. To date there is very limited literature regarding this topic due to small number of cases. Primary malignant melanoma of the vagina usually occurs in women aged in their 60s or 70s, with the majority of patients being postmenopausal. Patients commonly complain of vaginal bleeding, vaginal discharge or a palpable mass. The gold standard of diagnosis is established by pathologic examination. Management of vaginal melanoma depends on its staging. In early disease, tumor can be removed by wide localized excision with tumor free margin 1-2 cm depending on Breslow depth. In advanced disease, a radical surgery in addition to adjuvant therapy (chemo-, radio-, or immunotherapy) is performed. Currently, there is no optimal treatment regimen for vaginal melanoma. We present a case report of a 49-years-old female with vaginal melanoma stage IVA with urethral involvement and inguinal lymph node infiltration. We decided to perform radical surgery consisting of total hysterectomy, vaginectomy and urethral augmentation with pedicle flap from ileum .

Keywords: Readiness, challenge, ASN, teknologi, society 5.0

Introduction

Primary vaginal cancers are a rare entity, accounting for less than 3% of all the diagnosed female reproductive tract cancers. Among them, the majority of them are squamous cell cancers, and malignant melanoma only accounts for about 5% of them. This makes the occurrence of primary malignant melanoma of the vagina an infrequent entity, accounting for only 0.46 cases per million women per year (Paravathaneni, Keshava, Baralo, & Thirumaran, 2020). Vaginal melanoma arises from abnormally located melanocytes in the vaginal epidermis. It is an embryological remnant of the neural crest cell. Vaginal melanoma is very rare (2,6% of all primary vaginal cancer) and aggressive in nature (Gardner et al., 2015). The most common presenting symptom

for vaginal melanoma is vaginal bleeding (60%-100%); vaginal masses, pain, or discharge are other reported symptoms. Approximately 10% of patients will be asymptomatic.

The following examination for vaginal cancer diagnosis is by biopsy. Histopathology is the gold standard for diagnosis of malignant melanoma. Immunohistochemistry still an important ancillary inquiry. There is no specific laboratory examination or biomarker to diagnose vaginal cancer (Morgado, 2021). Imaging modalities using MRI and PET-CT are used to guide therapy and evaluate post-therapeutic change. To date, there is no effective treatment strategy for vaginal cancer. Current treatment plan consists of wide local excision, radical surgery, chemotherapy, immunotherapy, combination therapy, and palliative care (Gershenwald et al., 2017).

A 49-years-old patient presented to gynecology clinic with chief complaint of vaginal mass since 7 months prior. Patient also complained of whitish, non-odorous vaginal discharge with no pruritus and brownish-red spotting alternately. She had her menopause 2 years ago. There was no abdominal pain or body weight decrement. During urination, the patient felt a little pain (VAS 3-4) and burn sensation. There is no complaint of defecation. Patient was diagnosed with hypertension 3 years ago. Patient had her first menstruation at 15 years old and had regular menstruation cycle. This was her first marriage and blessed with 2 children, both delivered through cesarean section due to premature rupture of membrane and gestational hypertension. She used DMPA 3 month injection as her contraception method. Patient appeared alert with high blood pressure (173/93 mmHg), heart rate 91 beats per minute, respiration rate 20 times per minute, and temperature 36°C. Body mass index was at 35 kg/m². There was unremarkable finding on general examination.

Gynecology examination showed a mass with diameter of 5 cm on anterior vagina. Cervical portio was smooth, normal in size, with no mass palpated. Biopsy of the mass showed malignant tumor, suggestive of vaginal melanoma. During 2 months preparation for surgery, patient started complaining of increased urinary frequency and urgency.

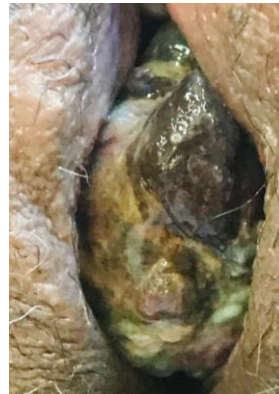
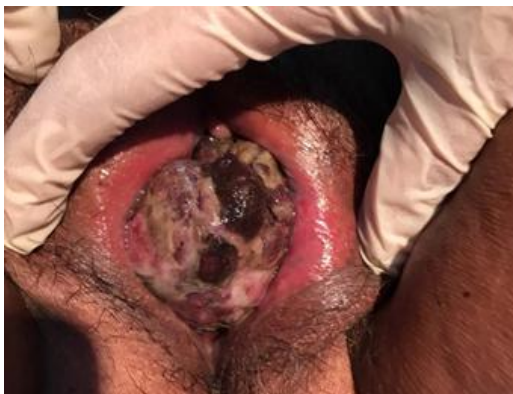
Image 1

Mass On Distal Third Of The Anterior Vagina Wall

Proceeded to performed biopsy and sent to Hystopathology Laboratorium. The result was malignant melanoma. Ultrasound examination showed vaginal mass with urethral infiltration. We decided to put suprapubic catheter to alleviate urinary symptoms. Pelvic MRI examination showed tumor in distal vagina with urethral and inguinal node infiltration. We decided to perform radical hysterectomy and total vaginectomy in this patient. During procedure, we identified the mass which already infiltrated the urethra. Part of the urethra was removed alongside the vagina. We then perform urethral augmentation using distal ileum segment to make neourethra by laparotomy approach. Ileum harvested was connected with bladder neck (Image 6a). The distal part was made to be urethra orificium (Image 7). Patient was in good condition post operation with little pain (VAS 1-2) and stable hemodynamic status. Further pathological analyses of the specimen confirmed that the tumor was a primary vaginal melanoma. Immunocytochemistry results revealed that the tumoral cells were positive for HMB45, Melan-A, and S-100. Other result was 50% positive for KI-67, CD56, AE1/AE3, P40, Syanpathophysin and Chromogranin were negative. After operation patient felt mass enlargement on both inguinal area and genital. Neouretra was non vital and there was stricture, therefor patient still on cystotomy. Patient underwent chemotherapy with Carboplatin and Paclitaxel.

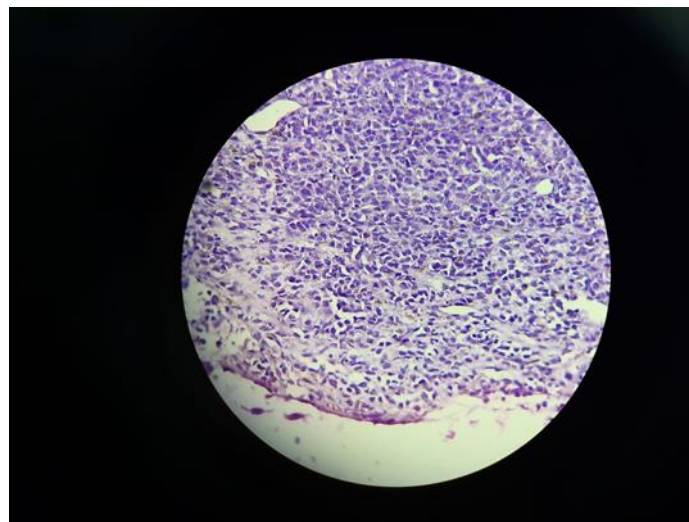


Image 2
Histopathology Examination Showing Melanocytic Part

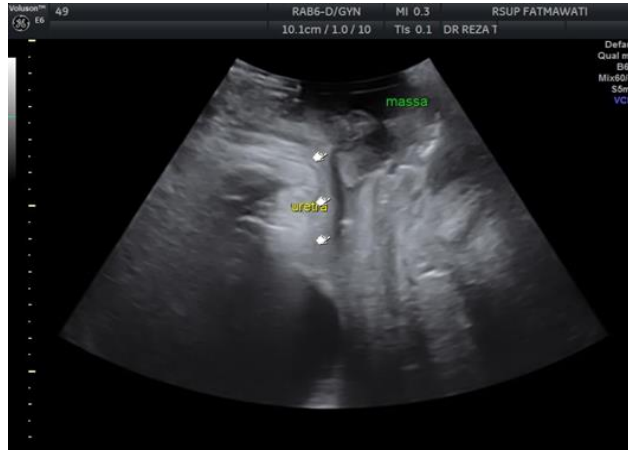

Image 3
Ultrasound Examination Showing Vaginal Mass Infiltration To Urethra

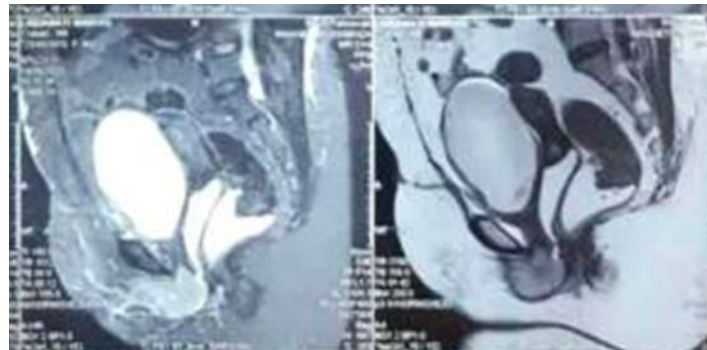

Image 4
MRI Showed Distal Vaginal Mass Sized 43x39x31 mm, Infiltrated To Urethra With Lateral Superficial Inguinal Lymph Node Enlargement < 1 cm.

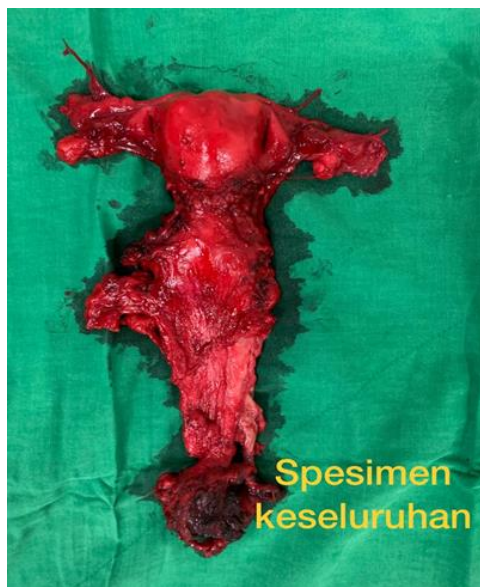

Image 5
Radical Hysterectomy Showing Uterus With Normal Size And Shape

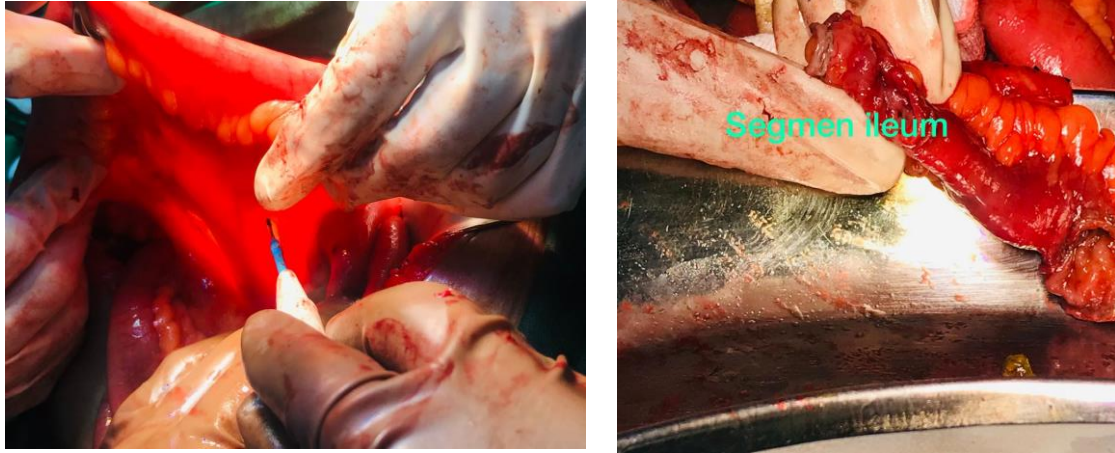


Image 6

**a. Identified The Ileum And Made Pedicle Flap To Reconstructed Distal Urethra.
B.Ileum Segment Use For Neourethra**

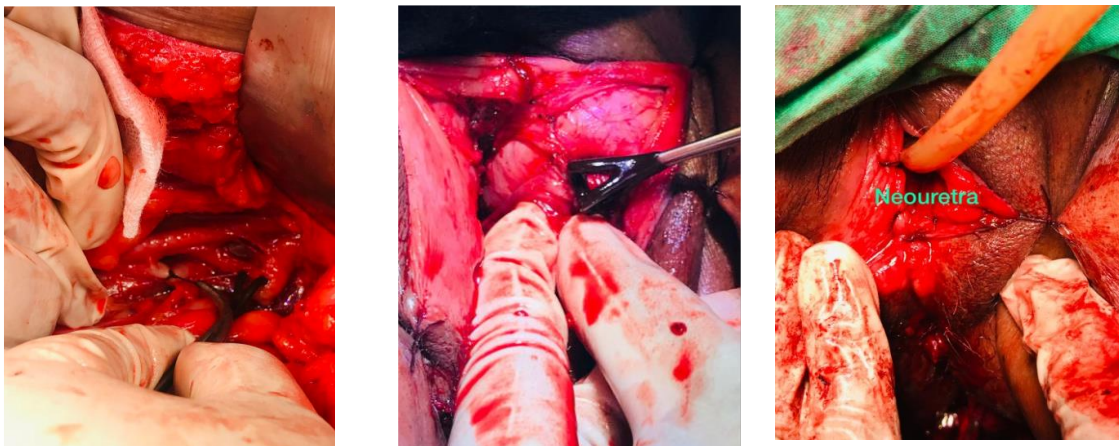


Image 7

**(a) . The Proximal Ileum Punctum Was Sutured In 6 Clockwise Directions (b). The Distal Segment Of The Ileum Was Sutured Interruptedly To The Vaginal Mucosa.
(c). Distal Ileum Connected To Bladder Neck To Made Neourethra**

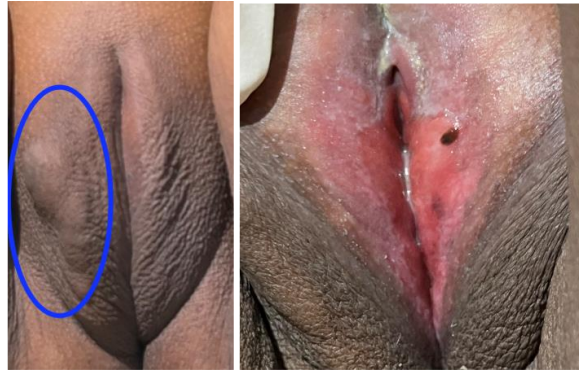

Image 8

a. Mass On Right Labia Majora. b. Stricture Post Neourethra

Research Methods

This is a case report of our patient who come to Oncology Gynecology Clinic of RSUP Fatmawati. The Patient underwent surgery on November 2020.

Results and Discussion

Vaginal cancer, especially the melanoma type, is a very rare and aggressive gynecology cancer with little documentation. There were only 37 reported cases of vaginal melanoma in 29 year period. The incidence is 0,46 per one million women. The mechanism regarding etiology and pathogenesis of this malignancy is still unknown. Some authors suggest that it might be associated with ultraviolet radiation. Others proposed that it is associated with mutation of KIT gene which responsible for encoding c-KIT protein. Multiple copies of this protein are expressed on mucosal melanoma. The gold standard to diagnose this malignancy is by pathological examination. Staging and risk assessment procedures are determined by disease presentation at diagnosis. Physical examination with special attention to any suspicious pigmented lesions, tumour satellites, in-transit metastases (ITM), regional lymph node (LN) and systemic metastases is mandatory.

In low-risk melanomas (pT1a), no additional investigations are necessary. In the other T stages, pT1b-pT4b, ultrasound (US) for locoregional LN metastasis, and/or computed tomography (CT) or positron emission tomography (PET) scans as well as brain magnetic resonance imaging (MRI), represent options for tumour extension assessment before surgical treatment and SN biopsy (SNB). Brain MRI and PET-CT/CT scan should be applied only for very high-risk patients (pT3b and higher [III, C]). The eighth version of the AJCC staging and classification system, which includes SN staging, is the preferred classification system (Kalampokas, Kalampokas, & Damaskos, 2017).

A preoperative biopsy of the mass is an advisable method to improve tumor detection in patients with a primary malignant melanoma of the vagina.

Immunohistochemical staining positive for vimentin, protein S-100, Melan A, and HMB-45 should also be used to confirm the diagnosis (Chen et al., 2014).

As mentioned previously, there are various treatments option for vaginal cancer. The mainstay treatment for resectable vaginal cancer is surgery. Literature showed that patient undergoing surgery had better survival chance compared to those only receiving radiotherapy. For early stage tumor, the popular surgical method is wide local excision with safety margin of 1-2 cm depending on the Breslow depth. For advanced stage tumor, a radical surgery (total hysterectomy, vaginectomy, and/or vulvectomy) and lymphadenectomy along with chemo- or radiotherapy is performed depending on the location and infiltration of the tumor. The surgical approaches, including wide local excision, total vaginectomy, or radical extirpation with en bloc removal of the involved pelvic organs, have been considered the most important potentially curative options, which could increase the chances of a longer survival time of the patient, as compared with those treated non-surgically (Chen et al., 2014). However, the optimal treatment approach to improve survival is still unknown due to small number of cases.5 Some literatures stated that radical surgery has better results compared to wide local excision, while other literatures stated that the disease free survival and overall survival from both approach is not significantly different (Räber, Mempel, Jackisch, & Schneider, 1993). Other debatable surgical procedure is whether to dissect a clinically negative lymph nodes infiltration or not. Lymphatic drainage from the lower third of the vagina and vulva goes to the superficial and deep inguinal lymph nodes or the deep pelvic lymph nodes. Due to low rate of lymph node metastasis, routine lymphatic dissection is not performed. It is recommended to evaluate sentinel node involvement by radiopharmaceutical-directed mapping technique, dye injection method, or laparoscopic ultrasonographic detection to determine whether lymph nodes removal is needed (Gershenwald et al., 2017).

In cases of inoperable tumor in advanced diseases or poor general condition, treatment with chemo-, radio-, or immunotherapy could be performed. Agents used for chemotherapy are dacarbazine, temozolomide, paclitaxel, nitrosurea, imatinib, midostaurin, and vincristine. Although chemotherapy does not cure the disease, it helps prolong survival and reduce pain (Frumovitz et al., 2010). Radiotherapy is found to be effective in managing incomplete tumor resection and pelvic metastasis post operatively. It could also be used pre-operatively to reduce tumor size. It is not recommended as a sole treatment for vaginal melanoma, but may be considered in cases where patients refuse operation (Kocayörük, Barut, Duran, & Tekinbaş, n.d.). Immunotherapy using interferon-alpha-2b is found to be effective in preventing tumor relapse. It could be combined with chemotherapy, but its effectiveness has yet to be proven and it has been associated with increased toxicity (Piura, 2008).

Prognosis of vaginal melanoma depends on a lot of factors, such as age, FIGO stage, tumor size and location, depth of invasion, histology, venous invasion, etc. The overall 5-year survival rate is 0-25%, irrespective to treatment. Patients presenting with tumor smaller than 3 cm survived for 41 months while patients presenting with tumor

larger than 3 cm only survived for 12 months. Infiltration to lymph nodes decreased survival rate to only 5% within 3-year period ([Gershenwald et al., 2017](#)).

In our case we diagnosed the patient with vaginal melanoma stage IVA due to urethral involvement. Further imaging studies showed no sign of distant metastasis. Patient had advanced disease with poor prognosis. We decided to do radical surgery consist of total hysterectomy and vaginectomy with urethral augmentation.

After surgery patient proceed with chemotherapy using two agent, Carboplatin and Paclitaxel. Common agents currently being used in practice include dacarbazine, temozolomide, nitrosourea, and paclitaxel with or without cisplatin or carboplatin ([Leitao et al., 2014](#)). Activity was reported in mucosal melanoma with chemotherapy and biochemotherapy but little in-depth data is given to draw any firm conclusions about response rates and specific therapies. Other reports of chemotherapy in mucosal melanoma suggest some activity with carboplatin paclitaxel (113) in the pretreated population; however, there is little data specific to the Ano-Uro-Genital mucosal melanoma group, which means that robust evidence based recommendations are not possible ([Lin et al., 2011](#)).

BIBLIOGRAFI

- Chen, Lifeng, Xiong, Yin, Wang, Huan, Liang, Lizhi, Shang, Huiling, & Yan, Xiaojian. (2014). Malignant melanoma of the vagina: A case report and review of the literature. *Oncology Letters*, 8(4), 1585–1588. [Google Scholar](#)
- Frumovitz, Michael, Etchepareborda, Mariano, Sun, Charlotte C., Soliman, Pamela T., Eifel, Patricia J., Levenback, Charles F., & Ramirez, Pedro T. (2010). Primary malignant melanoma of the vagina. *Obstetrics & Gynecology*, 116(6), 1358–1365. [Google Scholar](#)
- Gardner, C. S., Sunil, J., Klopp, A. H., Devine, C. E., Sagebiel, T., Viswanathan, C., & Bhosale, P. R. (2015). Primary vaginal cancer: role of MRI in diagnosis, staging and treatment. *The British Journal of Radiology*, 88(1052), 20150033. [Google Scholar](#)
- Gershenwald, Jeffrey E., Scolyer, Richard A., Hess, Kenneth R., Sondak, Vernon K., Long, Georgina V, Ross, Merrick I., Lazar, Alexander J., Faries, Mark B., Kirkwood, John M., & McArthur, Grant A. (2017). Melanoma staging: evidence-based changes in the American Joint Committee on Cancer eighth edition cancer staging manual. *CA: A Cancer Journal for Clinicians*, 67(6), 472–492. [Google Scholar](#)
- Kalampokas, Emmanouil, Kalampokas, Theodoros, & Damaskos, Christos. (2017). Primary vaginal melanoma, a rare and aggressive entity. A case report and review of the literature. *In Vivo*, 31(1), 133–139. [Google Scholar](#)
- KOCAYÖRÜK, Ercan, BARUT, Yaşar, DURAN, Volkan, & TEKİNBAŞ, Murat. (n.d.). *Rehberlik ve Psikolojik Danışma*. [Google Scholar](#)
- Leitao, Mario M., Cheng, Xi, Hamilton, Anne L., Siddiqui, Nadeem A., Jurgenliemk-Schulz, Ina, Mahner, Sven, Åvall-Lundqvist, Elisabeth, Kim, Kidong, & Freyer, Gilles. (2014). Gynecologic Cancer InterGroup (GCIG) consensus review for vulvovaginal melanomas. *International Journal of Gynecologic Cancer*, 24(Supp 3). [Google Scholar](#)
- Lin, Li Te, Liu, Chung Bin, Chen, San Nung, Chiang, An Jen, Liou, Wen Shiung, & Yu, Ken Jen. (2011). Primary malignant melanoma of the vagina with repeated local recurrences and brain metastasis. *Journal of the Chinese Medical Association*, 74(8), 376–379. [Google Scholar](#)
- Morgado, Maria Beatriz. (2021). Problemas sexuais na mulher com cancro da mama e cancro ginecológico: revisão narrativa. *Revista Portuguesa de Medicina Geral e Familiar*, 37(4), 314–328. [Google Scholar](#)
- Paravathaneni, Mahati, Keshava, Vinay Edlukudige, Baralo, Bohdan, & Thirumarani, Rajesh. (2020). Primary Vaginal Malignant Melanoma: A Case Report and Review of Literature. *Cureus*, 12(9). [Google Scholar](#)

Piura, Benjamin. (2008). Management of primary melanoma of the female urogenital tract. *The Lancet Oncology*, 9(10), 973–981. [Google Scholar](#)

Räber, G., Mempel, V., Jackisch, C., & Schneider, H. P. (1993). Clinical aspects of primary malignant melanoma of the vagina. *Zentralblatt Fur Gynakologie*, 115(9), 416–422. [Google Scholar](#)

Copyright holder:

Octaviyana Nadia NS, Sukma Dewi Pawestri, Reyhan Aditya, Fara Vitantri Diah C, Chamim (2022)

First publication right:

Syntax Literate: Jurnal Ilmiah Indonesia

This article is licensed under:

