

## ISCHEMIC STROKE AND SEVERE ACUTE RESPIRATORY DISTRESS SYNDROM IN A PATIENT CONFIRMED POSITIVE CORONAVIRUS DISEASE: CASE REPORT

I Gede Catur Wira Natanagara<sup>1</sup>, Ahmad Irfan<sup>2</sup>, Nurul Rakhmawati<sup>3</sup>, Efriadi Ismail<sup>4</sup>

General Practitioners Wisma Atlet Kemayoran COVID-19 Emergency Hospital<sup>1</sup>  
Anesthesiologist and Intensive Therapy Wisma Atlet Kemayoran COVID-19  
Emergency Hospital<sup>2</sup>

Neurologist Wisma Atlet Kemayoran COVID-19 Emergency Hospital<sup>3</sup>

Pulmonologist Wisma Atlet Kemayoran COVID-19 Emergency Hospital<sup>4</sup>

Email : caturwira@hotmail.com, a.irfan@gmail.com, n.rakhmawati@gmail.com,  
efriadi.ismail@gmail.com

### Abstract

The corona virus infection disease has become a pandemic for almost the last two years that has occurred in all countries including Indonesia. Covid 19 in its development can cause various complications, one of which is the occurrence of neurological disorders in addition to respiratory disorders. One of these neurological complications is stroke. In this case report, we will report a case of a patient who was confirmed positive for Covid 19 with complications of ischemic stroke at the Covid 19 Emergency Hospital Wisma Atlet Kemayoran. A 50-year-old male patient came confirmed positive for Covid 19 to the RSDC Wisma Atlet Kemayoran. The patient came with a cough since 5 days before going to the ER and was treated using HFNC and was intubated while in the ICU, the patient had decreased consciousness, weakness in the left extremity and seizures. The patient also had a history of hypertension and type II diabetes mellitus. Results Chest X-ray showed bilateral pneumonia and CT scan of the head showed right hemisphere infarction. The pathophysiology of stroke in Covid 19 is due to hyperactivation of inflammatory factors caused by systemic inflammation. In addition, ischemic stroke in Covid 19 patients can occur due to D-dimer and platelet abnormalities. In addition to respiratory disorders, Covid 19 can also cause neurological disorders that can increase morbidity in patients who suffer from it.

**Keywords:** Covid-19; ischemic stroke; severe acute respiratory distress syndrome; neurological disorder

### Introduction

The corona virus infection disease has become a pandemic for almost the last two years that has occurred in all countries including Indonesia. In July 2021 in Indonesia, there were 2.88 million positive cases with 75 thousand deaths and this number is increasing over time.

Covid 19 can cause various complications until various clinical symptoms appear in each patient. The most common complications are acute respiratory distress syndrome (ARDS), to other complications such as cardiovascular disorders, septic shock, impaired kidney function and neurological disorders. The most common neurological disorder is stroke. The relationship between Covid 19 and ARDS and stroke is not known for certain. The pathophysiology of neurological disorders and Covid 19 with ARDS has not been fully understood. Therefore, we report this case by considering ischemic stroke and Covid 19 patients with severe ARDS at the Wisma Atlet Hospital.

## 1. Case Report

A man, aged 50, came to the ER at the Wisma Atlet Kemayoran Hospital with a positive PCR swab result for Covid 19 accompanied by a cough since 5 days ago. In the initial examination, vital signs were found to be good, so the patient was given symptomatic treatment and continued isolation treatment in the Wisma Atlet RSDC room. After 3 days of treatment in the self-isolation room, the patient complained of shortness of breath accompanied by coughing up phlegm. Other complaints such as fever, runny nose, and diarrhea were denied by the patient. The patient previously had a history of uncontrolled diabetes mellitus.

On examination in the independent isolation room, vital signs were obtained such as blood pressure of 128/55, heart rate of 112x/minute, respiratory rate of 35-40x/minute with oxygen saturation of 65-70% with room air and 92-93% using NRM 15. lpm. On physical examination found tachypnea and the presence of effort in heavy breathing effort, on neurological and abdominal examination within normal limits. The patient was consulted to dr. Lung and dr. Anesthesia was decided by the patient to enter the ICU and intubate the patient.

After 12 days of treatment the patient had improved in his clinical condition and it was decided to extubate the patient and use HFNC. After 3 days of extubation, the patient again worsened where the patient had decreased consciousness, left extremity weakness and convulsions

On the hematological examination, routine blood, liver function, kidney function, electrolytes and D-dimer and aPTT were carried out on the first day and thereafter every 3 days of treatment.

## 2. Routine blood check

Parameter	10/06/21	13/06/21	17/06/21	22/06/21	26/06/21	01/07/21	05/07/21	12/07/21
Eritrosit	4,75	4,7	4.38	4.56	5.21	3.63	3.82	4.26
Hemoglobin	13.8	13,9	12.8	13.4	15.5	11	11.3	12
Hematokrit	38	37,5	36.7	38	42.6	31.1	33.6	36.2
MCV	80	79.8	83.8	83.3	81.8	85.7	88	85
MCH	29.1	29.6	29.2	29.4	29.8	30.3	30.3	35.1
Leukosit	7.07	9.1	9.94	13.92	25.03	17.1	13.9	10.5

Parameter	10/06/	13/06/	17/06/	22/06/	26/06/	01/07/	05/07/	12/07/2
	21	21	21	21	21	21	21	1
Trombosit	204	130	371	399	292	144	280	458
eo/ba/neu/lyp	0/0.80/	0/0/83/	0/0/87	0/0/85	0/0/88	0/0/90	0/0/75/	0/2/76/
h/mono	15/5	10/7	/8/5	/6/9	/6/6	/4/6	16/6	12/10

### 3. Liver and kidney function tests

Paramet er	10/06/2	13/06/2	17/06/2	22/06/2	26/6/2	01/07/2	05/07/2	12/07/2
	1	1	1	1	1	1	1	1
SGOT	558	156	30	23	40	254	145	121
SGPT	600	367	21	35	70	525	600	298
Ureum	42	32	53	55	75	57	68	67
Creatini n	1	0.46	0.6	0.9	0.9	0.6	0.68	0.7

### 4. Electrolyte

Paramet er	10/06/2	13/06/2	17/06/2	22/06/2	26/06/2	01/07/2	05/07/2	12/07/2
	1	1	1	1	1	1	1	1
Natrium	-	-	138	138	-	130	133	137
Kalium	-	-	3.8	3.9	-	5.9	4.3	3.7
Klorida	-	-	103	111	-	98	102	97

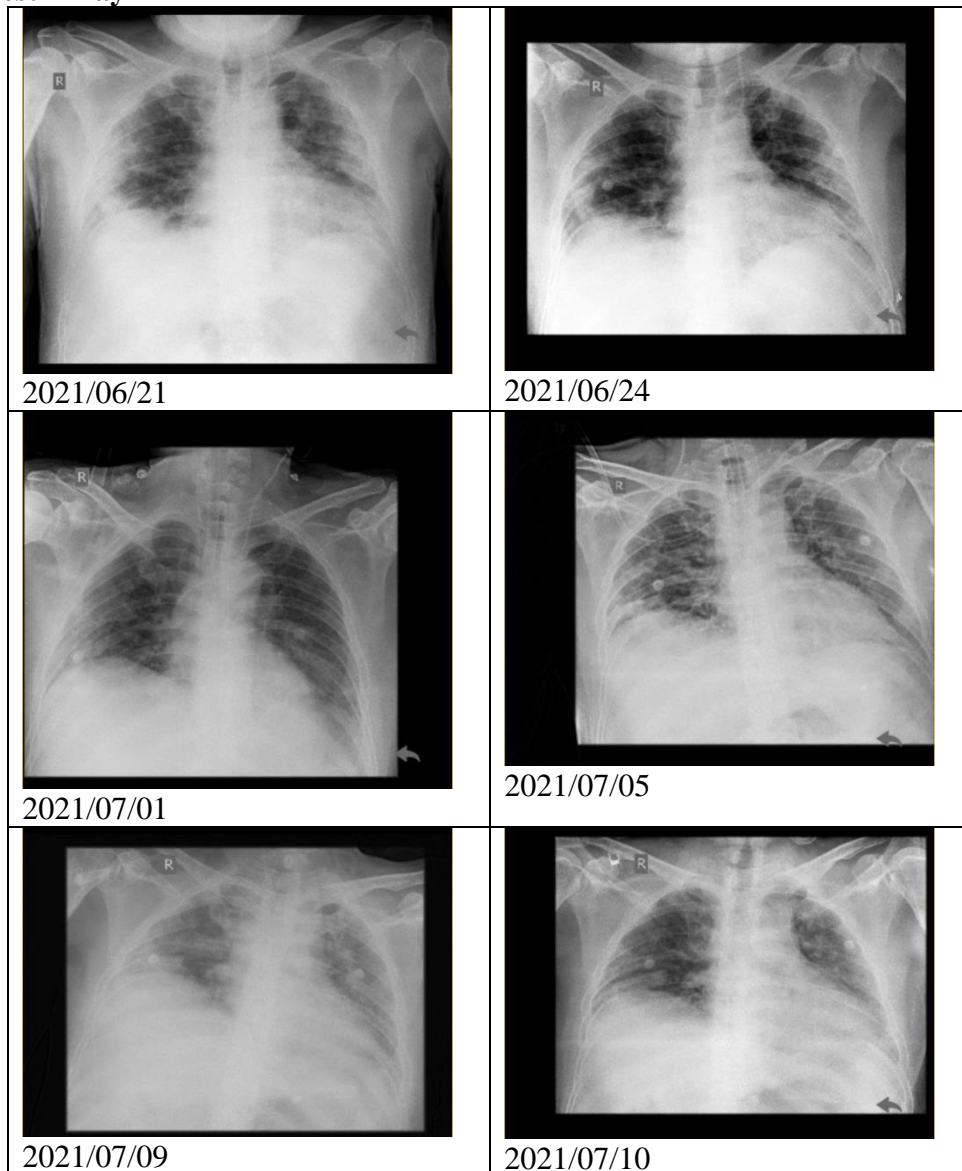
### 5. Blood Gas Analysis

Parameter	10/06/21	13/06/21 On Venti FiO2 65%	17/06/21 On Venti FiO2 70%	22/06/21 On HFNC FiO2 70%	-	01/07/21 On Venti FiO2 50%	05/07/21 On Venti FiO2 40%	-
pH	-	7.4	7.4	7.4	-	7.4	7.4	-
SaO2	-	96	97.4	89.5	-	100	98	-
PaCO3	-	34	27.4	24.2	-	42.6	40.6	-
PaO2	-	74.5	84.7	50.2	-	256	108	-
HCO3	-	24.1	20.6	20,6	-	30.6	28.2	-
BE	-	0.9	1.8	1.9	-	7	4	-
P/F Rasio	-	114	121	71.7	-	512	270	-

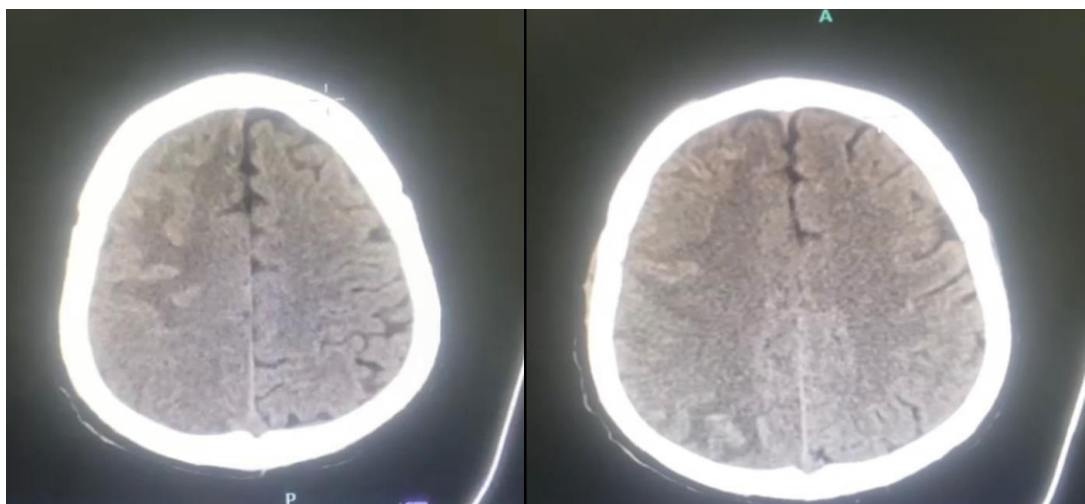
### 6. aPTT and D-dimer

Parameter	10/06/21	13/06/21	17/06/21	22/06/21	26/06/21	01/07/21	05/07/21	-
aPTT	-	58.6	38.2	102.2	37.6	30.5	-	-
D-dimer	-	-	>8.0000	2000	2500	>8000	>8000	-

### 7. Chest X-ray



### 8. Head CT Scan



CT scan of a patient with right hemispheric infarction with hemorrhagic transformation.

During treatment, the patient was treated with levofloxacin 1x750mg, Reopenem 3x1gr, ampicillin sulbactam 3x1,5gr, remdesivir loading dose 200mg then 1x100mg, acetylcysteine drip 5gr, fluconazole loading dose 400mg then 1x200mg, dexamethasone, heparin. Patients are also given multivitamins such as vitamin D3 1x5000iu, becefort 2x1, zinc 1x20mg, curcuma 3x1 and symptomatic treatment during treatment.

### **Method Research**

This case report is a patient who was treated at the Covid-19 Emergency Hospital Wisma Atlet Kemayoran who was treated during June-July 2021

### **Discussion**

This case report tells about a confirmed Covid 19 patient with severe symptoms who had an ischemic stroke after undergoing treatment at the Kemayoran Wisma Atlet Hospital. The patient had a history of previously uncontrolled diabetes mellitus and hypertension. Diabetes mellitus and hypertension are the biggest factors in the occurrence of ischemic stroke.

The lung is the organ most affected by COVID-19, with massive alveolar damage, edema, inflammatory cell infiltration, microvascular thrombosis, vascular damage and hemorrhage (Chen et al., 2021). With the occurrence of damage can still cause problems in breathing and the occurrence of respiratory failure. Respiratory failure caused by COVID-19 causes acute respiratory distress syndrome (ARDS) which requires assisted ventilation (Orsucci, Ienco, Nocita, Napolitano, & Vista, 2020). In line with the incidence of hypoxia, brain damage will occur due to reduced oxygen intake to the brain. Autopsies on patients with COVID-19 found neural damage in the brain areas most susceptible to hypoxia, including the neocortex, hippocampus and cerebellum (Sharifian-Dorche et al., 2020)

The pathophysiology of stroke due to COVID-19 is caused by increased hyperactivity of inflammatory factors which also causes cytokine storm syndrome and disorders of the coagulation system that cause increased D-Dimers and abnormalities in platelets (Chen et al., 2021), (Agarwal et al., 2020), (Ellul et al., 2020)

Coronavirus can also have an effect on bone marrow cells causing inhibition of hematopoiesis (Sharifian-Dorche et al., 2020). This leads to a decrease in lymphocytes, the formation of platelets that causes thrombocytopenia (Hanafi et al., 2020). It also causes a prolongation of the partial activation of the thromboplastin time and an increase in D-dimer levels (Hanafi et al., 2020).

Another thing that can happen to coagulopathic COVID-19 patients is that it causes some serious and dangerous complications of the disease (Espinosa, Rizvi, Sharma, Hindi, & Filatov, 2020). In a multicenter study, 88% of patients showed evidence of an increased hypercoagulable state. The coagulopathy of COVID-19 is

characterized by a characteristic pro-coagulant state with increased clot strength, increased D-dimer (a fibrin breakdown product indicating intravascular thrombosis), and increased fibrinogen, without significant changes in platelet count or prolongation of clotting time parameters (Espinosa et al., 2020). Coagulopathy and thrombosis may originate in the lungs and other infected organs with endothelial damage, complement activation, procoagulant effect of IL-6, recruitment of neutrophils. Furthermore, neutrophils release extracellular traps (NETs) in COVID-19, a sequence of chromatin and histones that activate blood clots, which contribute to intravascular thrombosis by capturing cells and platelets in various organs including the brain (Siow et al., 2021)

Cerebrovascular manifestations are found in 2-6% of COVID-19 patients. Most are ischemic strokes (Siow et al., 2021). Most of them are over 60 years old, and many of them have risk factors for cerebrovascular disease, such as hypertension, diabetes, hyperlipidemia, and other vascular diseases (Orrù et al., 2020)

There are several possible etiopathological explanations for the incidence of stroke in COVID-19 patients, ranging from inflammation-induced venous and arterial thromboembolism and hypoxia to diffuse intravascular coagulation. A correlation was found between cytokine release, encephalopathy and stroke symptoms in COVID-19 patients with cortical stroke. Data also show that influenza virus is able to trigger a cytokine cascade and cause exacerbation of ischemic brain damage and intracerebral hemorrhage after treatment with tissue plasminogen activator. Virus-induced cytokine release that ultimately causes cerebrovascular dysfunction could be one possible mechanism by which COVID-19 infection causes stroke.

Arterial and venous imaging studies are important in COVID-19 patients with acute cerebrovascular events (Ellul et al., 2020). Blood D-dimer concentrations are elevated in many patients with COVID-19, which is consistent with a pro-inflammatory, coagulopathic condition in the critical illness setting (Orrù et al., 2020). Positive lupus anticoagulant, anticardiolipin, and anti-beta2-glycoprotein-1 antibodies have also been reported in COVID-19-associated stroke, although they may be elevated in other critical illness conditions, including infection (Shehata et al., 2021)

In COVID-19 and stroke patients, administration of tPA may be beneficial. It is unclear whether other anticoagulants such as low molecular weight heparin (LWMH) or full-dose heparin should be given. There is evidence that LWMH may be useful in the setting of sepsis-induced coagulopathy. Prompt anticoagulation with LWMH has been recommended for COVID-19 patients to reduce the risk of thrombotic disease. (14-16) In the case report, patients who have experienced severe ARDS and use breathing apparatus during their treatment experience neurological disorders caused by direct or indirect effects. This causes the patient to experience persistent neurological disorders that require time to recover and require rehabilitation facilities.

## Conclusion

Patients with confirmed COVID-19 with ARDS are at risk of developing neurological disorders such as ischemic stroke. An understanding of the

pathophysiology of COVID-19 infection is needed in the occurrence of neurological disorders. So that they can provide services in a comprehensive manner according to the course of the patient's disease.

## REFERENCE

- Agarwal, Amit, Pinho, Marco, Raj, Karuna, Yu, Frank F., Bathla, Girish, Achilleos, Michael, O'Neill, Thomas, Still, Michael, & Maldjian, Joseph. (2020). Neurological emergencies associated with COVID-19: stroke and beyond. *Emergency Radiology*, 27(6), 747–754. [Google Scholar](#)
- Chen, Xiangliang, Laurent, Sarah, Onur, Oezguer A., Kleineberg, Nina N., Fink, Gereon R., Schweitzer, Finja, & Warnke, Clemens. (2021). A systematic review of neurological symptoms and complications of COVID-19. *Journal of Neurology*, 268(2), 392–402. [Google Scholar](#)
- Ellul, Mark A., Benjamin, Laura, Singh, Bhagteshwar, Lant, Suzannah, Michael, Benedict Daniel, Easton, Ava, Kneen, Rachel, Defres, Sylviane, Sejvar, Jim, & Solomon, Tom. (2020). Neurological associations of COVID-19. *The Lancet Neurology*, 19(9), 767–783. [Google Scholar](#)
- Espinosa, Patricio S., Rizvi, Zufe, Sharma, Pamraj, Hindi, Fawzi, & Filatov, Asia. (2020). Neurological complications of coronavirus disease (COVID-19): encephalopathy, MRI brain and cerebrospinal fluid findings: case 2. *Cureus*, 12(5). [Google Scholar](#)
- Hanafi, R., Roger, P. A., Perin, B., Kuchcinski, G., Deleval, N., Dallery, F., Michel, D., Haccin-Bey, L., Pruvo, J. P., & Outteryck, O. (2020). COVID-19 neurologic complication with CNS vasculitis-like pattern. *American Journal of Neuroradiology*, 41(8), 1384–1387. [Google Scholar](#)
- Orrù, Graziella, Conversano, Ciro, Malloggi, Eleonora, Francesconi, Francesca, Ciacchini, Rebecca, & Gemignani, Angelo. (2020). Neurological complications of COVID-19 and possible neuroinvasion pathways: a systematic review. *International Journal of Environmental Research and Public Health*, 17(18), 6688. [Google Scholar](#)
- Orsucci, Daniele, Ienco, Elena, Caldarazzo, Nocita, Gianpaolo, Napolitano, Alessandro, & Vista, Marco. (2020). Neurological features of COVID-19 and their treatment: a review. *Drugs in Context*, 9. [Google Scholar](#)
- Sharifian-Dorche, Maryam, Huot, Philippe, Osherov, Michael, Wen, Dingke, Saveriano, Alexander, Giacomini, Paul S., Antel, Jack P., & Mowla, Ashkan. (2020). Neurological complications of coronavirus infection; a comparative review and lessons learned during the COVID-19 pandemic. *Journal of the Neurological Sciences*, 417, 117085. [Google Scholar](#)
- Shehata, Ghaydaa A., Lord, Kevin C., Grudzinski, Michaela C., Elsayed, Mohamed, Abdelnaby, Ramy, & Elshabrawy, Hatem A. (2021). Neurological complications of COVID-19: Underlying mechanisms and management. *International Journal of Molecular Sciences*, 22(8), 4081. [Google Scholar](#)



I Gede Catur Wira Natanagara, Ahmad Irfan, Nurul Rakhmawati, Efriadi Ismail

Taherifard E, Taherifard E. Neurological complications of COVID-19: a systematic review. *Neurological Research*. 2020;42(11):905-12.

Siow, Isabel, Lee, Keng Siang, Zhang, John J. Y., Saffari, Seyed Ehsan, Ng, Adeline, & Young, Barnaby. (2021). Stroke as a neurological complication of COVID-19: a systematic review and meta-analysis of incidence, outcomes and predictors. *Journal of Stroke and Cerebrovascular Diseases*, 30(3), 105549. [Google Scholar](#)

Carod-Artal FJ. Neurological complications of coronavirus and COVID-19. *Revista de neurologia*. 2020;70(9):311-22.

Chachkhiani D, Soliman MY, Barua D, Isakadze M, Villemarette-Pittman NR, Devier DJ, et al. Neurological complications in a predominantly African American sample of COVID-19 predict worse outcomes during hospitalization. *Clinical neurology and neurosurgery*. 2020;197:106173

---

**Copyright holder:**

I Gede Catur Wira Natanagara, Ahmad Irfan, Nurul Rakhmawati, Efriadi Ismail (2022)

**First publication right:**

Syntax Literate: Jurnal Ilmiah Indonesia

**This article is licensed under:**

